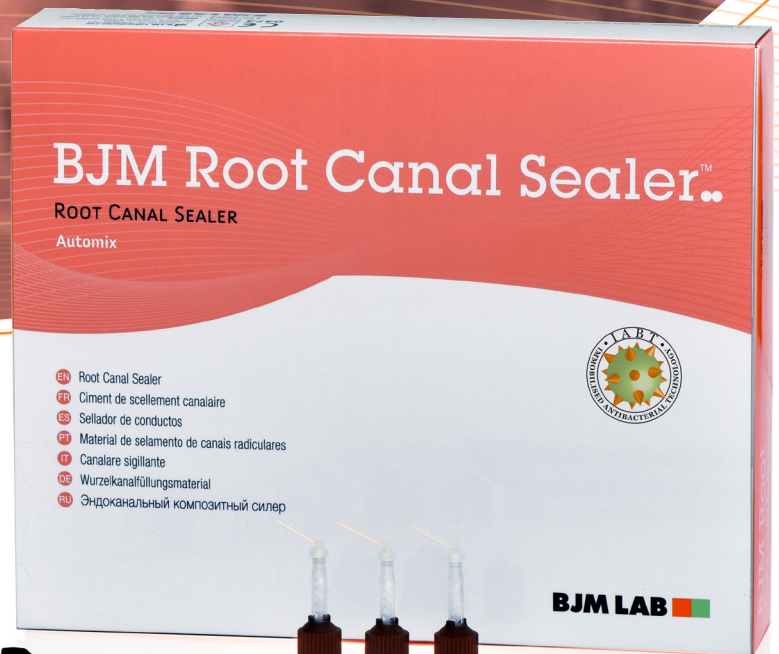

BJM Root Canal Sealer™

TWO-PASTE EPOXY-AMINE
RESIN ROOT CANAL SEALER



IABT incorporation into dental polymers prevents bacterial growth and biofilm formation.

Indications

- Obturation of root canals together with gutta-percha points.

Properties

- Extremely high radiopacity.
- Excellent wettability and flow properties.
- Outstanding sealing ability.
- IABT Antibacterial technology.
- Non-cytotoxic.
- Long-term stability.
- Moderate flexibility that prevents cracking of fully cured material.
- Low shrinkage.
- Automix Syringe - Saves application time; guarantees consistent mix.

Scientific Papers

1. Antibacterial mechanism of novel endodontic sealer, D. Kesler Shvero, N. Zaltsman, E. Weiss, N. Beyth, Hadassah School of Dental Medicine, Hebrew University, IADR Israeli Division Meeting, Tel-Aviv, June 2013.
2. Root canal sealers as Biofilm prevention: facts and speculations, M. Solomonov, Эндодонтия, Том VII, No. 1-2, 2014.
3. Antibiofilm Activity of Epoxy Sealer with Quaternary Ammonium Macromolecule, T. Becker, M.

Solomonov, N. Sterer, R. Bar-Ness, A. Levin, A. Shemesh, The Maurice and Gabriela Goldschleger School of Dental Medicine Tel Aviv University, Program Number 0219, PER-IADR Congress, Jerusalem, Israel, 2016.

4. Dr. Michael Solomonov, Clinical Cases Report, March 2017.
5. Evaluating the physical properties of one novel and two well-established epoxy resin-based root canal sealers, M. Solomonov, J.B. Itzhak, Quintessence Publishing Endo 2017; 11 (4): 285-290.
6. Antibiofilm activity of epoxy sealer incorporated with quaternary ammonium macromolecule, T. Becker, N. Sterer, R. Bar-Ness, T. Toledano and M. Solomonov Evidence-Based Endodontics 2019; 4 (1): 1-6.
7. Dr. Gabriel Kaplan, Clinical Cases Report, March 2019.

Technical Data

BJM RCS will set within 48 hours at 37°C

Shelf Life

2 Years

Packaging & Order Information

- Item # 400200

- 1 Automix Syringe 5ml of BJM RCS
- 10 Automix Syringe Mix Tips and Intraoral Tips
- 1 Mixing Pad



Dr. Gabriel Kaplan

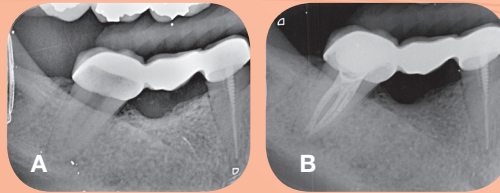
Graduated from the Universidad Latino-Americana Mexico D.F in 1995 and completed his postgraduate in Endodontics in 1998 at the UNITEC University in Mexico. Since then he practice at his private clinic in Israel that is dedicated exclusively to Endodontics.

"I strive to deliver the best endodontic treatment possible and it includes using the best materials that provides me the reassurance for clinical successes. I find BJM materials to be an important part of our clinical success and provide me with consistence results throughout the years."

CASE 1.

Pulp necrosis treatment

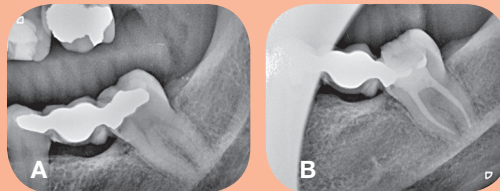
A 54 year old women with history of swelling and pain from tooth number 47, took antibiotics and now is asymptomatic. Diagnosis of necrotic pulp and apical periodontitis. RCT was done with PTN and GP+BJM Root Canal Sealer.



CASE 2.

Acute pulpitis treatment

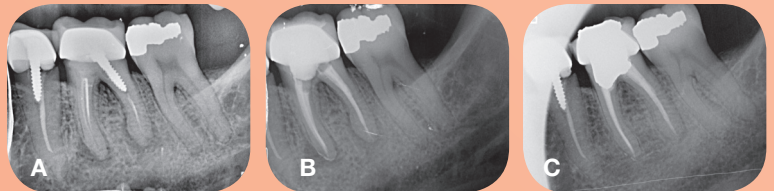
A 45 year old women with acute pulpitis tooth number 37, she requested to save the bridge so the treatment was made without removing the prosthetics. Treatment was made with PTN and GP+BJM Root Canal Sealer.



CASE 3.

Apical periodontitis treatment

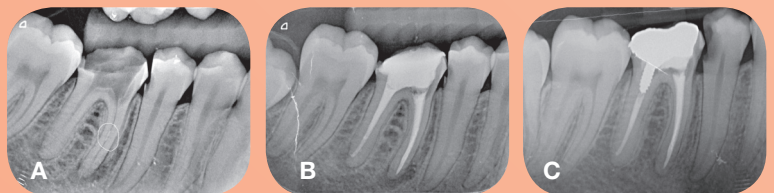
A 40 years old women complaining on pain to percussion and on biting, she had the RCT and prosthetic done years before. Diagnosis of apical periodontitis was made and retreatment of RCT was done in 2 sittings, with PTN and Calxyl dressing. Second appointment- obturation with GP+BJM Root Canal Sealer. Follow up after 18 month.



CASE 4.

Broken instrument removal

A 20 years old man was referred after RCT was initiated in another clinic. Tooth number 46- without temporary filling, broken instrument in MB canal and apical periodontitis. Patient was asymptomatic. RCT was done in 2 appointment after the instrument was removed and calxyl dressing. GP+BJM Root Canal Sealer. Follow up after 3 years.



CASE 5.

Periapical periodontitis treatment

A 46 years old women, tooth number 36, asymptomatic with periapical periodontitis. Reatreatment of RCT was done in 2 appointments with Calxyl canal dressing. Tooth was obturated with GP+BJM Root Canal Sealer. Follow up after 6 month.

